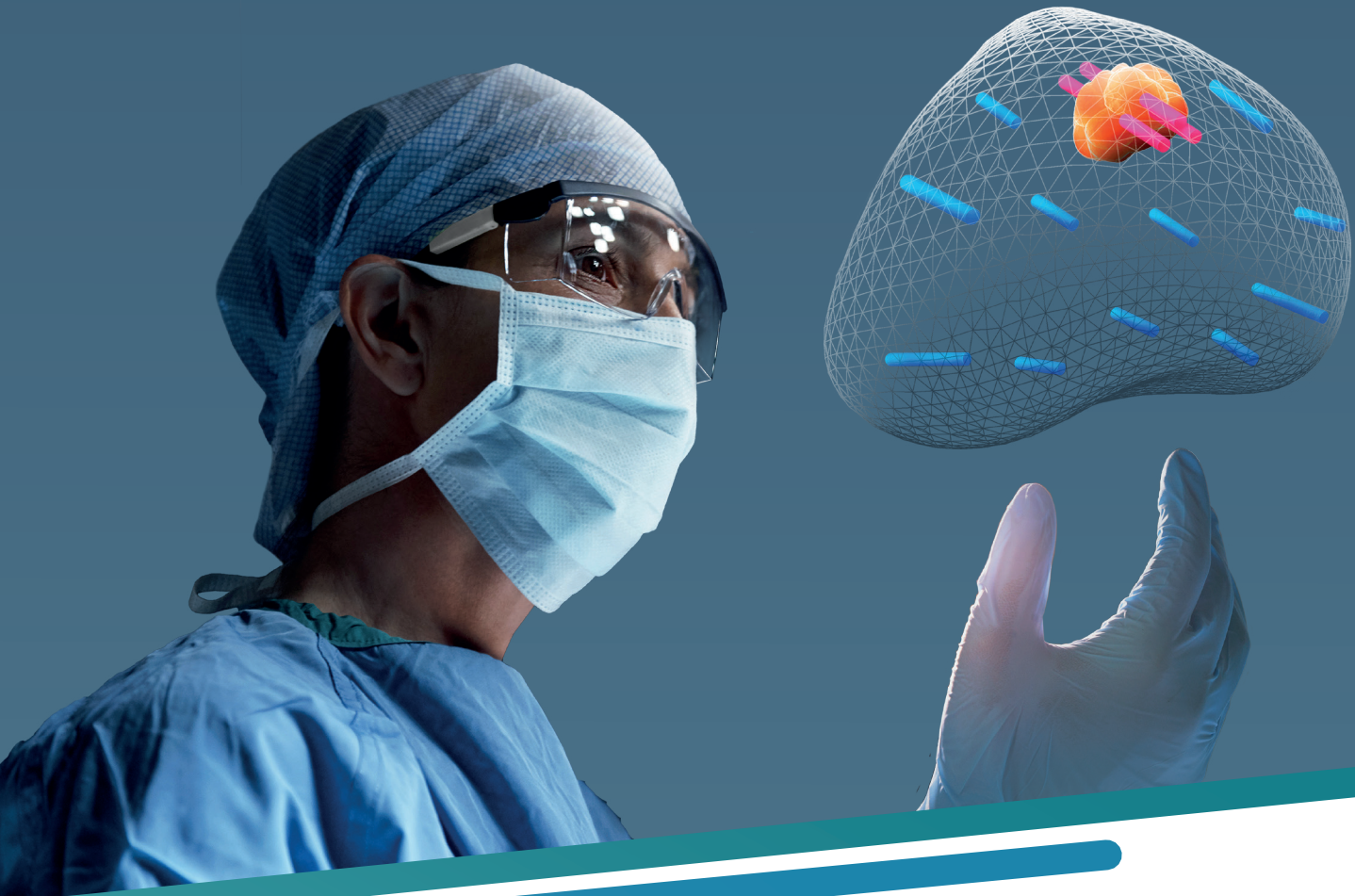

See Beyond  
Prostate Biopsy.



**KOELIS BEST PAPERS**  
4<sup>th</sup> Edition - 2009 - 2020



# CONTENTS

|  |           |
|--|-----------|
| DIAGNOSTIC ACCURACY.....                                   | 4         |
| <i>MRI/US TARGETED BIOPSY.....</i>                         | <i>4</i>  |
| <i>3D ULTRASOUND GUIDED BIOPSY.....</i>                    | <i>14</i> |
| <i>PRECISION OF THE OBT* FUSION®.....</i>                  | <i>16</i> |
| CLINICAL PRACTICE.....                                     | 20        |
| <i>TRANSPERINEAL BIOPSY UNDER LOCAL ANESTHESIA.....</i>    | <i>20</i> |
| BEYOND PROSTATE BIOPSY.....                                | 25        |
| <i>DIAGNOSTIC ACCURACY: PET/US TARGETED BIOPSY.....</i>    | <i>25</i> |
| <i>REPEAT BIOPSY FOR ACTIVE SURVEILLANCE STRATEGY.....</i> | <i>28</i> |
| <i>FOCAL TREATMENT.....</i>                                | <i>32</i> |
| BIBLIOGRAPHY.....  | 36        |

\*ORGAN BASED TRACKING®

## IMPROVEMENT OF THE INTERMEDIATE RISK PROSTATE CANCER SUB-CLASSIFICATION BY INTEGRATING MRI AND FUSION BIOPSY FEATURES

Roumiguié M<sup>1</sup>, Lesourd M, Zgheib J, Tollon C, Salin A, Alméras C, Doumerc N, Thoulouzan M, Soulié M, Gautier J-R, Loison G, Assoun J, Vacher A, Aziza R, Bernard Malavaud B, Beauval J-B, Ploussard G.

<sup>1</sup> Department of Urology, CHU Toulouse, Toulouse, France. Department of Urology, La Croix du Sud Hospital, Quint Fonsegrives, France. Department of Urology, Institut Universitaire du Cancer Toulouse - Oncopole, Toulouse, France. Department of Radiology, La Croix du Sud Hospital, Quint Fonsegrives, France. Department of Radiology, Institut Universitaire du Cancer Toulouse - Oncopole, Toulouse, France.

Urol Oncol. 2020

**INTRODUCTION:** Treatment decision-making for intermediate-risk prostate cancer (CaP) is mainly based on grade and tumor involvement on systematic biopsy. We aimed to assess the added value of multi-parametric magnetic resonance imaging (mpMRI) and targeted biopsy (TB) features for predicting final pathology and for improving the well-established favourable/unfavourable systematic biopsy-based sub-classification.

**MATERIALS AND METHODS:** From a prospective database of 377 intermediate risk CaP cases, we evaluated the performance of the standard intermediate risk classification (IRC), and the predictive factors for unfavourable disease on final pathology aiming to build a new model. Overall unfavourable disease (OUD) was defined by any pT3-4 and/or pN1 and/or grade group (GG)  $\geq 3$ .

**RESULTS:** The standard IRC was found to be predictive for unfavourable disease in this population. However, in multivariable analysis regression, ECE on mpMRI and GG  $\geq 3$  on TB remained the 2 independent predictive factors for OUD disease (HR = 2.7, P = 0.032, and HR = 2.41, P = 0.01, respectively). By using the new IRC in which unfavorable risk was defined by ECE on mpMRI and/or GG  $\geq 3$  on TB, the proportion of unfavorable cases decreased from 62.3% to 34.1% while better predicting unfavorable disease in RP specimens. The new model displayed a better accuracy than the standard IRC for predicting OUD (AUC: 0.66 vs. 0.55).

**CONCLUSIONS:** The integration of imaging and TB features drastically improves the intermediate risk sub-classification performance and better discriminates the unfavourable risk group that could benefit from more aggressive therapy such as neo-adjuvant and/or adjuvant treatment, and the favourable group that could avoid over-treatment. External validation in other datasets is needed.

## ACCURACY OF ELASTIC FUSION BIOPSY IN DAILY PRACTICE: RESULTS OF A MULTICENTER STUDY OF 2115 PATIENTS

Oderda M, Marra G, Albisinni S, Altobelli E, Baco E, Beatrici V, Cantiani A, Carbone A, Ciccariello M, Descotes JL, Dubreuil-Chambardel M, Eldred-Evans D, Fasolis G, Ferriero M, Fiard G, Forte V, Giacobbe A, Kumar P, Lacetera V, Mozer P, Muto G, Papalia R, Pastore A, Peltier A, Piechaud T, Simone G, Roche JB, Roupret M, Rouviere O, Van Velthoven R, Gontero P.

Int J Urol. 2018

**OBJECTIVES:** To assess the accuracy of Koelis fusion biopsy for the detection of prostate cancer and clinically significant prostate cancer in the everyday practice.

**METHODS:** We retrospectively enrolled 2115 patients from 15 institutions in four European countries undergoing transrectal Koelis fusion biopsy from 2010 to 2017. A variable number of target (usually 2-4) and random cores (usually 10-14) were carried out, depending on the clinical case and institution habits. The overall and clinically significant prostate cancer detection rates were assessed, evaluating the diagnostic role of additional random biopsies. The cancer detection rate was correlated to multiparametric magnetic resonance imaging features and clinical variables.

**RESULTS:** The mean number of targeted and random cores taken were 3.9 (standard deviation 2.1) and 10.5 (standard deviation 5.0), respectively. The cancer detection rate of Koelis biopsies was 58% for all cancers and 43% for clinically significant prostate cancer. The performance of additional, random cores improved the cancer detection rate of 13% for all cancers ( $P < 0.001$ ) and 9% for clinically significant prostate cancer ( $P < 0.001$ ). Prostate cancer was detected in 31%, 66% and 89% of patients with lesions scored as Prostate Imaging Reporting and Data System 3, 4 and 5, respectively. Clinical stage and Prostate Imaging Reporting and Data System score were predictors of prostate cancer detection in multivariate analyses. Prostate-specific antigen was associated with prostate cancer detection only for clinically significant prostate cancer.

**CONCLUSIONS:** Koelis fusion biopsy offers a good cancer detection rate, which is increased in patients with a high Prostate Imaging Reporting and Data System score and clinical stage. The performance of additional, random cores seems unavoidable for correct sampling. In our experience, the Prostate Imaging Reporting and Data System score and clinical stage are predictors of prostate cancer and clinically significant prostate cancer detection; prostate-specific antigen is associated only with clinically significant prostate cancer detection, and a higher number of biopsy cores are not associated with a higher cancer detection rate.


|  | Target biopsies only | Target + random biopsies | P      |
|--|----------------------|--------------------------|--------|
| <b>PCa detection on biopsy</b>                                   |                      |                          |        |
| CDR  | 965 (45.6%)          | 1230 (58.2%)             | <0.001 |
| <b>PCa Gleason score</b>   |                      |                          |        |
| GS 6   | 357 (37.3%)          | 461 (40.1%)              | 0.14   |
| GS 7   | 437 (45.7%)          | 493 (42.8%)              | 0.25   |
| GS 8-10  | 162 (16.9%)          | 197 (17.1%)              | 0.86   |
| Missing  | 9                    | 79                       |        |
| <b>PCa detection according to DRE</b>                            |                      |                          |        |
| Negative   | 494 (65.9%)          | 664 (69.0%)              | 0.17   |
| Positive   | 256 (34.1%)          | 299 (31.0%)              | 0.17   |
| Missing  | 215                  | 266                      |        |
| <b>PCa detection according to size</b>                           |                      |                          |        |
| <10 mm   | 256 (45.6%)          | 305 (46.7%)              | 0.70   |
| ≥10 mm   | 305 (54.4%)          | 348 (53.3%)              | 0.70   |
| Missing  | 404                  | 577                      |        |
| <b>PCa detection according to PI-RADS</b>                        |                      |                          |        |
| 3  | 144 (15.7%)          | 208 (17.8%)              | 0.20   |
| 4  | 450 (49.0%)          | 595 (51.0%)              | 0.36   |
| 5  | 325 (35.4%)          | 363 (31.1%)              | 0.03   |
| Missing  | 46                   | 64                       |        |
| <b>PCa detection according to previous biopsy</b>                |                      |                          |        |
| Biopsy naïve   | 371 (52.9%)          | 420 (48.6%)              | 0.08   |
| Previous negative biopsies                                       | 299 (42.7%)          | 393 (45.4%)              | 0.27   |
| Patients in active surveillance                                  | 31 (4.4%)            | 52 (6%)                  | 0.16   |
| Missing  | 264                  | 365                      |        |
| <b>Clinically significant PCa detection on biopsy</b>            |                      |                          |        |
| Clinically significant CDR                                       | 716 (33.9%)          | 909 (43.0%)              | <0.001 |
| <b>Clinically significant PCa detection according to PI-RADS</b> |                      |                          |        |
| 3  | 77 (11.3%)           | 114 (13.2%)              | 0.29   |
| 4  | 334 (48.9%)          | 426 (49.4%)              | 0.84   |
| 5  | 272 (39.8%)          | 323 (37.4%)              | 0.36   |
| Missing  | 33                   | 48                       |        |

Figure 1. Biopsy results in terms of PCa and clinically significant PCa detection, comparing target biopsies only with target + random biopsies

# ACCURACY OF ELASTIC FUSION BIOPSY IN DAILY PRACTICE RESULTS OF A MULTICENTER STUDY OF 2115 PATIENTS

ODERDA ET AL., INT J UROL, AUGUST 2018

## PATIENTS



## METHODS

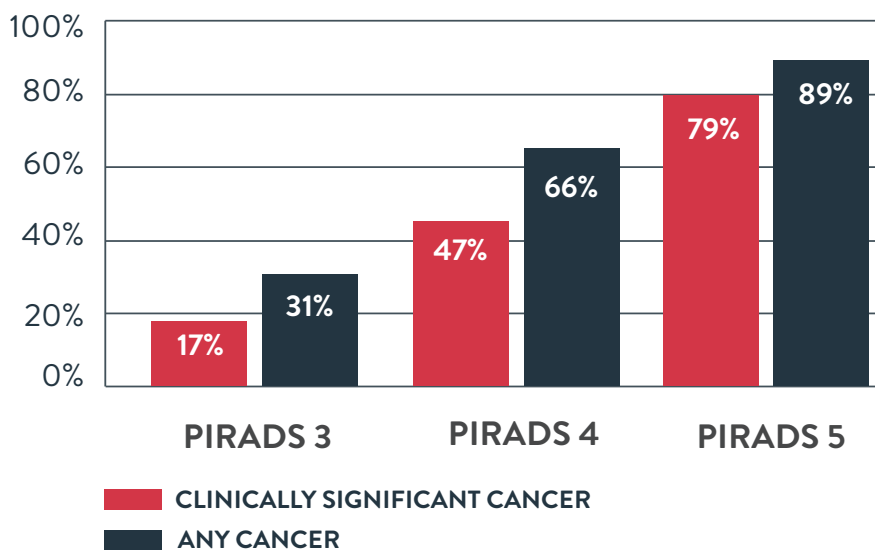
KOELIS PROSTATE MRI/US FUSION

2-4 TARGETED  
10-14 RANDOM



## RESULTS

DETECTION RATES ACCORDING TO PIRADS SCORE



## USE OF PROSTATE SYSTEMATIC AND TARGETED BIOPSY ON THE BASIS OF MULTIPARAMETRIC MRI IN BIOPSY-NAIVE PATIENTS (MRI-FIRST): A PROSPECTIVE, MULTICENTRE, PAIRED DIAGNOSTIC STUDY

Rouvière O, Puech P, Renard-Penna R, Claudon M, Roy C, Mège-Lechevallier F, Decaussin-Petrucci M, Dubreuil-Chambardel M, Magaud L, Remontet L, Ruffion A, Colombel M, Crouzet S, Schott A, Lemaitre L, Rabilloud M, Grenier N, for the MRI-FIRST Investigators\*

Lancet Oncol 2018

**BACKGROUND:** Whether multiparametric MRI improves the detection of clinically significant prostate cancer and avoids the need for systematic biopsy in biopsy-naive patients remains controversial. We aimed to investigate whether using this approach before biopsy would improve detection of clinically significant prostate cancer in biopsy-naive patients.

**METHODS:** In this prospective, multicentre, paired diagnostic study, done at 16 centres in France, we enrolled patients aged 18–75 years with prostate-specific antigen concentrations of 20 ng/mL or less, and with stage T2c or lower prostate cancer. Eligible patients had been referred for prostate multiparametric MRI before a first set of prostate biopsies, with a planned interval of less than 3 months between MRI and biopsies. An operator masked to multiparametric MRI results did a systematic biopsy by obtaining 12 systematic cores and up to two cores targeting hypoechoic lesions. In the same patient, another operator targeted up to two lesions seen on MRI with a Likert score of 3 or higher (three cores per lesion) using targeted biopsy based on multiparametric MRI findings. Patients with negative multiparametric MRI (Likert score  $\leq 2$ ) had systematic biopsy only. The primary outcome was the detection of clinically significant prostate cancer of International Society of Urological Pathology grade group 2 or higher (csPCa-A), analysed in all patients who received both systematic and targeted biopsies and whose results from both were available for pathological central review, including patients who had protocol deviations. This study is registered with ClinicalTrials.gov, number NCT02485379, and is closed to new participants.

**FINDINGS:** Between July 15, 2015, and Aug 11, 2016, we enrolled 275 patients. 24 (9%) were excluded from the analysis. 53 (21%) of 251 analysed patients had negative (Likert  $\leq 2$ ) multiparametric MRI. csPCa-A was detected in 94 (37%) of 251 patients. 13 (14%) of these 94 patients were diagnosed by systematic biopsy only, 19 (20%) by targeted biopsy only, and 62 (66%) by both techniques. Detection of csPCa-A by systematic biopsy (29.9%, 95% CI 24.3–36.0) and targeted biopsy (32.3%, 26.5–38.4) did not differ significantly ( $p=0.38$ ). csPCa-A would have been missed in 5.2% (95% CI 2.8–8.7) of patients had systematic biopsy not been done, and in 7.6% (4.6–11.6) of patients had targeted biopsy not been done. Four grade 3 post-biopsy adverse events were reported (3 cases of prostatitis, and 1 case of urinary retention with haematuria).

**INTERPRETATION:** There was no difference between systematic biopsy and targeted biopsy in the detection of ISUP grade group 2 or higher prostate cancer; however, this detection was improved by combining both techniques and both techniques showed substantial added value. Thus, obtaining a multiparametric MRI before biopsy in biopsy-naive patients can improve the detection of clinically significant prostate cancer but does not seem to avoid the need for systematic biopsy.

## MRI-TARGETED OR STANDARD BIOPSY FOR PROSTATE-CANCER DIAGNOSIS

Kasivisvanathan V, M.R.C.S., Rannikko A.S, Borghi M, Panebianco V, Mynderse L.A, Vaarala M.H, Briganti A, Budäus L, Hellowell G, F.R.C.S.(Urol.), Hindley R.G, F.R.C.S.(Urol.), Monique J. Roobol M.J, Scott Eggener S, et al., for the PRECISION Study Group Collaborators\*

NEJM 2018

**BACKGROUND:** Multiparametric magnetic resonance imaging (MRI), with or without targeted biopsy, is an alternative to standard transrectal ultrasonography-guided biopsy for prostate-cancer detection in men with a raised prostate-specific antigen level who have not undergone biopsy. However, comparative evidence is limited.

**METHODS:** In a multicenter, randomized, noninferiority trial, we assigned men with a clinical suspicion of prostate cancer who had not undergone biopsy previously to undergo MRI, with or without targeted biopsy, or standard transrectal ultrasonography-guided biopsy. Men in the MRI-targeted biopsy group underwent a targeted biopsy (without standard biopsy cores) if the MRI was suggestive of prostate cancer; men whose MRI results were not suggestive of prostate cancer were not offered biopsy. Standard biopsy was a 10-to-12-core, transrectal ultrasonography-guided biopsy. The primary outcome was the proportion of men who received a diagnosis of clinically significant cancer. Secondary outcomes included the proportion of men who received a diagnosis of clinically insignificant cancer.

**RESULTS:** A total of 500 men underwent randomization. In the MRI-targeted biopsy group, 71 of 252 men (28%) had MRI results that were not suggestive of prostate cancer, so they did not undergo biopsy. Clinically significant cancer was detected in 95 men (38%) in the MRI-targeted biopsy group, as compared with 64 of 248 (26%) in the standard-biopsy group (adjusted difference, 12 percentage points; 95% confidence interval [CI], 4 to 20;  $P=0.005$ ). MRI, with or without targeted biopsy, was noninferior to standard biopsy, and the 95% confidence interval indicated the superiority of this strategy over standard biopsy. Fewer men in the MRI-targeted biopsy group than in the standard-biopsy group received a diagnosis of clinically insignificant cancer (adjusted difference, -13 percentage points; 95% CI, -19 to -7;  $P<0.001$ ).

**CONCLUSIONS:** The use of risk assessment with MRI before biopsy and MRI-targeted biopsy was superior to standard transrectal ultrasonography-guided biopsy in men at clinical risk for prostate cancer who had not undergone biopsy previously. (Funded by the National Institute for Health Research and the European Association of Urology Research Foundation; PRECISION ClinicalTrials.gov number, NCT02380027.)



## DETECTION OF PROSTATE CANCER USING MRI-ULTRASONOGRAPHY IMAGE-FUSION TARGETED BIOPSY IN AFRICAN-AMERICAN MEN

Shin T<sup>1,2</sup>, Smyth T.B, Ukimura O, Ahmadi N, Abreu A.L.d.C, Oishi M, Mimata H, Gill I.S.

<sup>1</sup> USC Institute of Urology, Keck School of Medicine, University of Southern California, Los Angeles, CA, USA.

<sup>2</sup> Department of Urology, Oita University, Oita, Japan.

BJU Int. 2017

**OBJECTIVE:** To assess the diagnostic yield of targeted prostate biopsy in African-American (A-A) men using image fusion of multi-parametric magnetic resonance imaging (mpMRI) with real-time transrectal ultrasonography (US).

**MATERIALS AND METHODS:** We retrospectively analysed 661 patients (117 A-A and 544 Caucasian) who had mpMRI before biopsy and then underwent MRI/US image-fusion targeted biopsy (FTB) between October 2012 and August 2015. The mpMRIs were reported on a 5-point Likert scale of suspicion. Clinically significant prostate cancer (CSPC) was defined as biopsy Gleason score  $\geq 7$ .

**RESULTS:** After controlling for age, prostate-specific antigen level and prostate volume, there were no significant differences between A-A and Caucasian men in the detection rate of overall cancer (35.0% vs 34.2%,  $P = 0.9$ ) and CSPC (18.8% vs 21.7%,  $P = 0.3$ ) with MRI/US FTB. There were no significant differences between the races in the location of dominant lesions on mpMRI, and in the proportion of 5-point Likert scoring. In A-A men, MRI/US FTB from the grade 4-5 lesions outperformed random biopsy in the detection rate of overall cancer (70.6% vs 37.2%,  $P = 0.003$ ) and CSPC (52.9% vs 12.4%,  $P < 0.001$ ). MRI/US FTB outperformed random biopsy in cancer core length (5.0 vs 2.4 mm,  $P = 0.001$ ), in cancer rate per core (24.9% vs 6.8%,  $P < 0.001$ ), and in efficiency for detecting one patient with CSPC (mean number of cores needed 13.3 vs 81.9,  $P < 0.001$ ), respectively.

**CONCLUSIONS:** Our key finding confirms a lack of racial difference in the detection rate of overall prostate cancers and CSPC with MRI/US FTB between A-A and Caucasian men. MRI/US FTB detected more CSPC using fewer cores compared with random biopsy.

# A RANDOMIZED CONTROLLED TRIAL TO ASSESS AND COMPARE THE OUTCOMES OF TWO-CORE PROSTATE BIOPSY GUIDED BY FUSED MAGNETIC RESONANCE AND TRANSRECTAL ULTRASOUND IMAGES AND TRADITIONAL 12-CORE SYSTEMATIC BIOPSY

Baco E<sup>1</sup>, Rud E, Eri LM, Moen G, Vlatkovic L, Svindland A, Eggesbø HB, Ukimura O.

<sup>1</sup>Department of Urology, Division for Cancer Medicine, Surgery and Transplantation, Oslo University Hospital



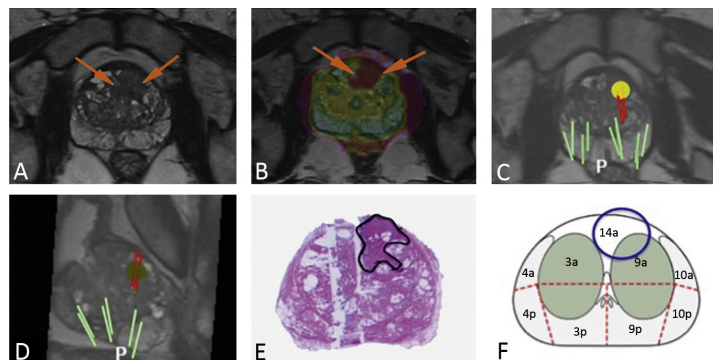
Eur Urol. 2016

**PURPOSE:** Prostate biopsy guided by computer-assisted fusion of magnetic resonance imaging (MRI) and transrectal ultrasound (TRUS) images (MRI group) has not yet been compared with 12-core random biopsy (RB; control group) in a randomized controlled trial (RCT).

**OBJECTIVE:** To compare the rate of detection of clinically significant prostate cancer (csPCa) between the two groups.

**DESIGN, SETTING, AND PARTICIPANTS:** This RCT included 175 biopsy-naïve patients with suspicion for prostate cancer, randomized to an MRI group (n=86) and a control group (n=89) between September 2011 and June 2013.

**INTERVENTION:** In the MRI group, two-core targeted biopsy (TB) guided by computer-assisted fusion of MRI/TRUS images of MRI-suspicious lesions was followed by 12-core RB. In the control group, both two-core TB for abnormal digital rectal examination (DRE) and/or TRUS-suspicious lesions and 12-core RB were performed. In patients with normal MRI or DRE/TRUS, only 12-core RB was performed.



**OUTCOMES MEASUREMENTS AND STATISTICAL ANALYSIS:** The detection rates for any cancer and csPCa were compared between the two groups and between TB and RB.

**RESULTS AND LIMITATIONS:** Detection rates for any cancer (MRI group 51/86, 59%; control group 48/89, 54%;  $p=0.4$ ) and csPCa (38/86, 44% vs 44/89, 49%;  $p=0.5$ ) did not significantly differ between the groups. Detection of csPCa was comparable between two-core MRI/TRUS-TB (33/86, 38%) and 12-core RB in the control group (44/89, 49%;  $p=0.2$ ). In a subset analysis of patients with normal DRE, csPCa detection was similar between two-core MRI/TRUS-TB (14/66, 21%) and 12-core RB in the control group (15/60, 25%;  $p=0.7$ ). Among biopsy-proven csPCas in MRI group, 87% (33/38) were detected by MRI/TRUS-TB. The definition of csPCa was only based on biopsy outcomes.

*Figure 1. Results for a 67-yr-old man with prostate-specific antigen of 7.2 ng/ml, a normal digital rectal examination, and a prostate volume of 75 ml. Prebiopsy magnetic resonance imaging (MRI) suggested anterior prostate cancer visible on (A) axial T2-weighted images and (B) an apparent diffusion coefficient map with color overlay (arrows). MRI/transrectal ultrasound (TRUS)-targeted biopsy (red bars), as demonstrated by (C) axial and (D) sagittal MRI/TRUS fused images, revealed Gleason 3 + 4 prostate cancer. The cancer core length was 9 and 5 mm (53% and 45% cancer core invasion). The patient was treated with radical prostatectomy. (E) A step-sectioned prostate specimen confirmed pT2 Gleason 3 + 4 prostate cancer. The tumor dimensions were 20 mm T 17 mm T 12 mm (2.2 ml) in the right anterior mid-gland region. (F) Positive biopsies (red bars) and the targeted region (yellow circle) shown in (C) and (D) corresponded to the three-dimensional tumor location in segment 10p.*

**CONCLUSION:** Overall csPCa detection was similar between the MRI and control groups. Two-core MRI/TRUS-TB was comparable to 12-core RB for csPCa detection.

**PATIENT SUMMARY:** Our randomized controlled trial revealed a similar rate of prostate cancer detection between targeted biopsy guided by magnetic resonance imaging (MRI) and transrectal ultrasound (TRUS) and 12-core random biopsy. The traditional 12-core random biopsy may be replaced by two-core MRI/TRUS targeted biopsy for detection of clinically significant prostate cancer.

## TRANSRECTAL ULTRASOUND-GUIDED PROSTATE BIOPSY FOR CANCER DETECTION: PERFORMANCE OF 2D-, 3D- AND 3D-MRI FUSION TARGETED TECHNIQUES

Klein J<sup>1</sup>, De Górski A, Benamran D, Vallee J-P, De Perrot T, Wirth G.J, Iselin C.E.

<sup>1</sup> Division of Urologic Surgery, Department of Surgery, Geneva University Hospital, Geneva, Switzerland.

Urol Int. 2016

**INTRODUCTION:** The study aimed to evaluate 3 different modalities of transrectal ultrasound (TRUS)-guided prostate biopsies (PBs; 2D-, 3D- and targeted 3D-TRUS with fusion to MRI – T3D). Primary end point was the detection rate of prostate cancer (PC). Secondary end point was the detection rate of insignificant PC according to the Epstein criteria.

**MATERIALS AND METHODS:** Inclusion of 284 subsequent patients who underwent 2D-, 3D- or T3D PB from 2011 to 2015. All patients having PB for initial PC detection with a serum prostate-specific antigen value  $\leq 20$  ng/ml were included. Patients with T4 and/or clinical and/or radiological metastatic disease, so as these under active surveillance were excluded.

**RESULTS:** Patients with T3D PB had a significantly higher detection rate of PC (58 vs. 19% for 2D and 38% for 3D biopsies;  $p = 0.001$ ), with no difference in Gleason score distribution ( $p = 0.644$ ), as well as detection rate of low-risk cancers ( $p = 0.914$ ). Main predictive factor for positive biopsies was the technique used, with respectively a 3- and 8-fold higher detection rate in the 3D- and T3D group. For T3D-PB, there was a significant correlation between radiological cancer suspicion (Prostate Imaging Reporting and Data System Score) and cancer detection rate ( $p = 0.02$ ).

**CONCLUSIONS:** T3D PB should be preferred over 2D PB and 3D PB in patients with suspected PC as it improves the cancer detection rate.

## PROSTATE IMAGING REPORTING AND DATA SYSTEM AND LIKERT SCORING SYSTEM: MULTIPARAMETRIC MR IMAGING VALIDATION STUDY TO SCREEN PATIENTS FOR INITIAL BIOPSY

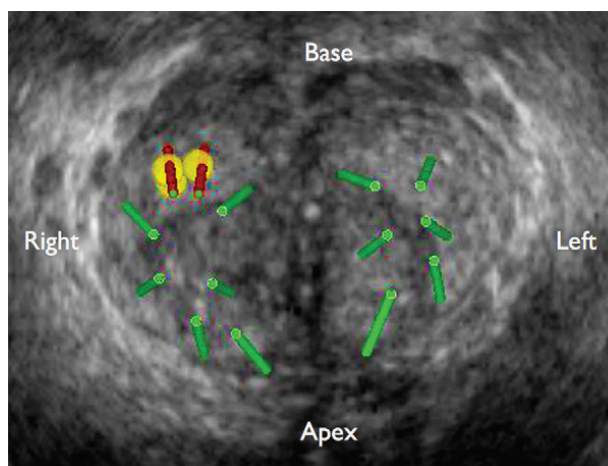
Renard-Penna R<sup>1</sup>, Mozer P, Cornud F, Barry-Delongchamps N, Bruguière E, Portalez D, Malavaud B.

<sup>1</sup>From the Departments of Radiology (R.R.) and Urology (P.M.), Hôpital Pitié-Salpêtrière, Paris, France; Department of Radiology, Hôpital Cochin, Paris, France (F.C., N.B.); and Departments of Radiology (E.B., D.P.) and Urology (B.M.), Institut Universitaire du Cancer

Radiology. 2015

**PURPOSE:** To compare the diagnostic performance of the magnetic resonance (MR) imaging-based Prostate Imaging Reporting and Data System (PI-RADS) and a Likert scale in the detection of prostate cancer in a cohort of patients undergoing initial prostate biopsy.

**MATERIALS AND METHODS:** This institutional review board-approved two-center prospective study included 118 patients with normal digital rectal examination (DRE) results but elevated prostate-specific antigen (PSA) levels (4-20 ng/mL) who were referred for initial prostate biopsies and had one suspicious (Likert scale score,  $\geq 3$ ) focus at prebiopsy 1.5-T multiparametric MR imaging performed with T2-weighted, diffusion-weighted [DW], and dynamic contrast material-enhanced imaging. Targeted core biopsies and random systematic core biopsies were performed. The elementary unit for analysis was the core. Relationships were assessed by using the Mann-Whitney U test. Yates corrected and Pearson  $\chi^2$  tests were used to evaluate categorical variables. A training set was randomly drawn to construct the receiver operating characteristic curves for the summed PI-RADS scores and for the Likert scale scores. The thresholds to recommend biopsy were obtained from the Youden J statistics and were tested in the remaining validation set in terms of predictive characteristics. Interobserver variability was analyzed by using weighed  $\kappa$  statistics in a random set of 50 patients.



**Figure 1.** Three-dimensional transrectal US fused image shows the location in the 1a sector of a suspicious focus (yellow; summed PI-RADS score at multiparametric MR imaging, 14) that was targeted by two targeted (red) cores in complement to 12 random (green) systematic cores in a 61-mL prostate.

**RESULTS:** Higher T2-weighted, DW, and dynamic contrast-enhanced imaging PI-RADS scores were observed in areas that yielded cancer-positive cores. The percentage of positive cores increased with the sum of scores aggregated in five classes as follows: For summed PI-RADS scores of 3-5, the percentage of positive cores was 2.3%; for scores of 6-8, it was 5.8%; for scores of 9 or 10, it was 24.7%; for scores of 11 or 12, it was 51.8%; and for scores of 13-15, it was 72.1% (P for trend,  $<.0001$ ). For the threshold of summed PI-RADS scores of 9 or greater, sensitivity was 86.6%, specificity was 82.4%, the positive predictive value was 52.4%, the negative predictive value was 96.5%, and accuracy was 83.2%. The respective data for Likert scale scores of 3 or greater were 93.8%, 73.6%, 44.3%, 98.1%, and 73.3%. Good interobserver agreement was observed for the Likert scale ( $\kappa = 0.80$ ) and the summed PI-RADS ( $\kappa = 0.73$ ) scoring systems.

**CONCLUSIONS:** PI-RADS provided the site-specific stratified risk of cancer-positive cores in biopsy-naive men with normal DRE results and elevated PSA levels. There was no significant difference between summed PI-RADS scores of 9 or greater and Likert scale scores of 3 or greater in the detection of cancer in the peripheral zone.

# FIRST ROUND OF TARGETED BIOPSIES USING MAGNETIC RESONANCE IMAGING/ULTRASONOGRAPHY FUSION COMPARED WITH CONVENTIONAL TRANSRECTAL ULTRASONOGRAPHY-GUIDED BIOPSIES FOR THE DIAGNOSIS OF LOCALISED PROSTATE CANCER

Mozer P<sup>1</sup>, Rouprêt M, Le Cossec C, Granger B, Comperat E, de Gorski A, Cussenot O, Renard-Penna R.

<sup>1</sup>Academic Department of Urology, AP-HP, Hôpital Pitié-Salpêtrière, Paris, France; UPMC University of Paris 06, Institut des Systèmes Intelligents et de Robotique.

BJUI. 2014

**OBJECTIVES:** To assess the accuracy of magnetic resonance imaging (MRI)/transrectal ultrasonography (TRUS) fusion to guide first-round biopsies in the diagnosis of localised prostate cancer (PCa) in men with a prostate-specific antigen (PSA)  $\leq 10$  ng/mL.

**PATIENTS AND METHODS:** A prospective study was conducted on men who met the following criteria: first-round biopsy, multiparametric MRI (mpMRI) showing a lesion with a Likert score  $\geq 2$  and a PSA  $< 10$  ng/mL. All men underwent an extended 12-core protocol plus a protocol of two or three targeted cores on the mpMRI index lesion. The UroStation (Koelis, Grenoble, France) and a V10 ultrasound system with an end-fire three-dimensional TRUS transducer were used for the fusion imaging procedure. Significant PCa was defined as: at least one core with a Gleason score of 3 + 4 or 6 with a maximum cancer core length  $\geq 4$  mm.

**RESULTS:** A total of 152 men, whose median PSA level was 6 ng/mL, were included in the study. The proportion of positive cores was significantly higher with the targeted-core protocol than with the extended 12-core protocol ( $P < 0.001$ ). The proportion of men with clinically significant PCa was higher with the targeted-core protocol than with the extended 12-core protocol ( $P = 0.03$ ). The proportion of patients having at least one positive biopsy (targeted-core protocol) was significantly different among the Likert score categories ( $P < 0.001$ ).

**CONCLUSIONS:** For the first round of biopsies, MRI/TRUS-fusion targeted biopsies detected more men with clinically significant PCa than did standard extended 12-core biopsy alone.

|  | Extended 12-core protocol | Targeted-core protocol | P      |
|--|---------------------------|------------------------|--------|
| Cores positive for clinically significant PCa, %                         | 7.5                       | 31                     | <0.001 |
| Men with clinically significant PCa detected, %                          | 37                        | 43                     | 0.03   |
| Median number of cores taken per diagnosis of clinically significant PCa | 12                        | 2                      | <0.001 |
| Median (IQR) length of positive cores, mm                                | 4 (2–8)                   | 8 (5–10)               | <0.001 |

PCa, prostate cancer; IQR, interquartile range.

Table 1. Comparisons of the two biopsy protocols (N = 152).

## 3D ULTRASOUND GUIDED BIOPSY

## 3D VERSUS 2D SYSTEMATIC TRANSRECTAL ULTRASOUND-GUIDED PROSTATE BIOPSY: HIGHER CANCER DETECTION RATE IN CLINICAL PRACTICE

Alexandre Peltier<sup>1,2</sup>, Fouad Aoun<sup>1&2</sup>, Fouad El-Khoury,<sup>1</sup> Eric Hawaux,<sup>1</sup> Ksenija Limani,<sup>1</sup> Krishna Narahari,<sup>1</sup> Nicolas Sirtaine,<sup>3</sup> and Roland Van Velthoven<sup>1,2</sup>

<sup>1</sup> Department of Urology, Jules Bordet Institute, 1 Rue Héger-Bordet, 1000 Brussels, Belgium

<sup>2</sup> Université Libre de Bruxelles, 50 Franklin Roosevelt Avenue, 1050 Brussels, Belgium

<sup>3</sup> Department of Anatomopathology, Jules Bordet Institute, 1 Rue Héger-Bordet, 1000 Brussels, Belgium

Hindawi. 2013

**PURPOSE:** To compare prostate cancer detection rates of extended 2D versus 3D biopsies and to further assess the clinical impact of this method in day-to-day practice.

**MATERIALS AND METHODS:** We analyzed the data of a cohort of 220 consecutive patients with no prior history of prostate cancer who underwent an initial prostate biopsy in daily practice due to an abnormal PSA and/or DRE using, respectively, the classical 2D and the new 3D systems. All the biopsies were done by a single experienced operator using the same standardized protocol.

**RESULTS:** There was no significant difference in terms of age, total PSA, or prostate volume between the two groups. However, cancer detection rate was significantly higher using the 3D versus the 2D system, 50% versus 34% ( $P < 0.05$ ). There was no statistically significant difference while comparing the 2 groups in term of nonsignificant cancer detection.

**CONCLUSIONS:** There is reasonable evidence demonstrating the superiority of the 3D-guided biopsies in detecting prostate cancers that would have been missed using the 2D extended protocol.

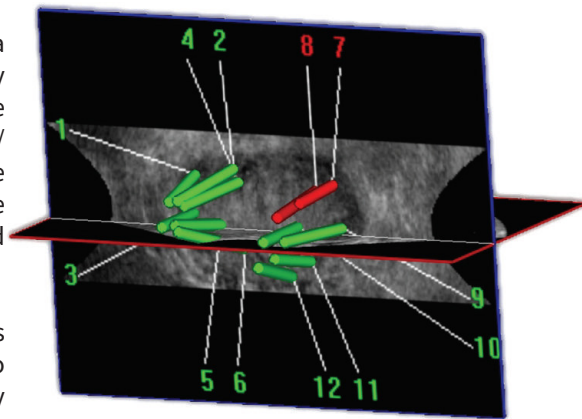


Figure 1. 3D trajectory visualization after biopsy along with mapping and cartography.

## MAPPING OF TRANSRECTAL ULTRASONOGRAPHIC PROSTATE BIOPSIES: QUALITY CONTROL AND LEARNING CURVE ASSESSMENT BY IMAGE PROCESSING

Mozer P<sup>1</sup>, Baumann M, Chevreau G, Moreau-Gaudry A, Bart S, Renard-Penna R, Comperat E, Conort P, Bitker MO, Chartier-Kastler E, Richard F, Troccaz J.

<sup>1</sup>Department of Urology, Assistance Publique-Hôpitaux de Paris, Paris, France

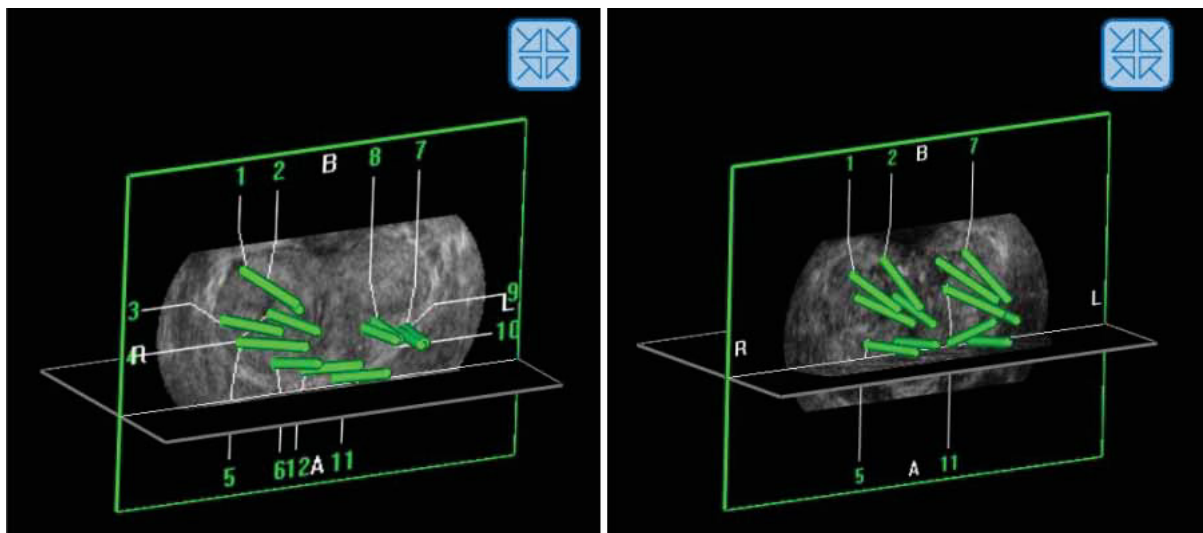
J US Med. 2009

**PURPOSE:** Mapping of transrectal ultrasonographic (TRUS) prostate biopsies is of fundamental importance for either diagnostic purposes or the management and treatment of prostate cancer, but the localization of the cores seems inaccurate. Our objective was to evaluate the capacities of an operator to plan transrectal prostate biopsies under 2-dimensional TRUS guidance using a registration algorithm to represent the localization of biopsies in a reference 3-dimensional ultrasonographic volume.

Thirty-two patients underwent a series of 12 prostate biopsies under local anesthesia performed by 1 operator using a TRUS probe combined with specific third-party software to verify that the biopsies were indeed conducted within the planned targets.

**RESULTS:** The operator reached 71% of the planned targets with substantial variability that depended on their localization (100% success rate for targets in the middle and right parasagittal parts versus 53% for targets in the left lateral base). Feedback from this system after each series of biopsies enabled the operator to significantly improve his dexterity over the course of time (first 16 patients: median score, 7 of 10 and cumulated median biopsy length in targets of 90 mm; last 16 patients, median score, 9 of 10 and a cumulated median length of 121 mm;  $P = .046$ ).

**CONCLUSIONS:** In addition to being a useful tool to improve the distribution of prostate biopsies, the potential of this system is above all the preparation of a detailed «map» of each patient showing biopsy zones without substantial changes in routine clinical practices.



**Figure 1.** Examples of biopsy distributions in the coronal plane for 2 different patients. Left, Patient from the first group, left base not sampled. Right, Patient from the second group, good sampling. A indicates apex; B, base; L, left; and R, right.

## PRECISION MATTERS IN MR IMAGING-TARGETED PROSTATE BIOPSIES: EVIDENCE FROM A PROSPECTIVE STUDY OF COGNITIVE AND ELASTIC FUSION REGISTRATION TRANSRECTAL BIOPSIES.

Cornud F<sup>1</sup>, Roumiguié M<sup>1</sup>, Barry de Longchamps N<sup>1</sup>, Ploussard G<sup>1</sup>, Bruguière E<sup>2</sup>, Portalez D<sup>2</sup>, Malavaud B<sup>2</sup>.

<sup>1</sup>Departments of Radiology (F.C.) and Urology (N.B.d.L.), Hôpital Cochin, Université Paris Descartes, Paris, France

<sup>2</sup>Institut Universitaire du Cancer, Toulouse

Radiology 2018

**PURPOSE:** To measure the precision in placement of a biopsy needle in a magnetic resonance (MR) imaging-detected target with transrectal ultrasonography (US), to document the clinical relevance of precision, and to report on the precision of cognitive and software-based registrations.

**PATIENTS AND METHODS:** This prospective study was approved by the institutional review board and performed between June 2013 and September 2013. Patients provided informed verbal consent. Two cores each were obtained with cognitive and fusion techniques in 88 patients with a Prostate Imaging Reporting and Data System version 1 score of at least 3. Precision was measured with Euclidian geometry by using the Digital Imaging and Communications in Medicine archives of the biopsy as the distance from the core to the center (dCC) and the distance from the core to the surface of the target modeled as a sphere. To address clustering of data from multiple cores in the same patients, analyses of precision focused on the best shot for a patient or a technique. The Welch unequal variance t test and Yates corrected x2 test were used as appropriate.

**RESULTS:** Mean precision was 2.5 mm (95% confidence interval: 1.8 mm, 3.3 mm). Positive cores were closer to the center than were negative cores (dCC: 1.7 mm vs 3.1 mm, respectively;  $P = .025$ ). More cancers were detected with on-target than off-target cores (33 of 71 cores [46.5%] vs three of 17 cores [17.6%];  $P = .03$ ). Cores obtained with the fusion technique achieved a higher precision than did cores obtained with the cognitive technique (dCC: 2.8 mm vs 7.1 mm, respectively;  $P < .0001$ ). Targeted cores demonstrated cancer in 44 patients. Fewer cancers were detected with the cognitive technique than with the fusion technique (31 of 44 patients [70.5%] vs 40 of 44 patients [90.9%];  $P = .03$ ).

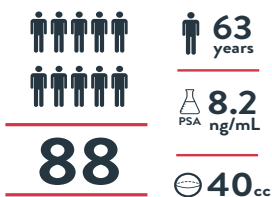
**CONCLUSION:** A deformable MR imaging/transrectal US image registration system achieved a higher precision and depicted cancer in more patients than did the cognitive freehand technique. was probably best than PET choline for detecting prostate cancer but it could be complementary.



# PRECISION MATTERS IN MR IMAGING-TARGETED PROSTATE BIOPSIES

CORNUD ET AL., RADIOLOGY, MAY 2018

## PATIENTS



## UROLOGISTS



## METHODS



## ON-TARGET vs OFF-TARGET

### CANCER TISSU SAMPLE



### CHANCE OF DEMONSTRATING CANCER



## COGNITIVE vs ELASTIC FUSION

### % OF POSITIVE CORES



| LOCATION OF TARGETS | PRECISION<br>Distance from the core to the center of the target |                     | INFORMATION<br>Distance from the core to the surface of the target |                     |
|---------------------|---|---------------------|--|---------------------|
|                     | COGNITIVE CORES (n=88)  | FUSION CORES (n=88) | COGNITIVE CORES (n=88)   | FUSION CORES (n=88) |
| BASE                | 8.4mm   | 3.6mm               | 4.0mm  | -0.8mm              |
| MID                 | 6.6mm   | 2.5mm               | 2.6mm  | -1.5mm              |
| APEX                | 6.3mm   | 2.3mm               | 1.6mm  | -2.4mm              |

© KOELIS 2018

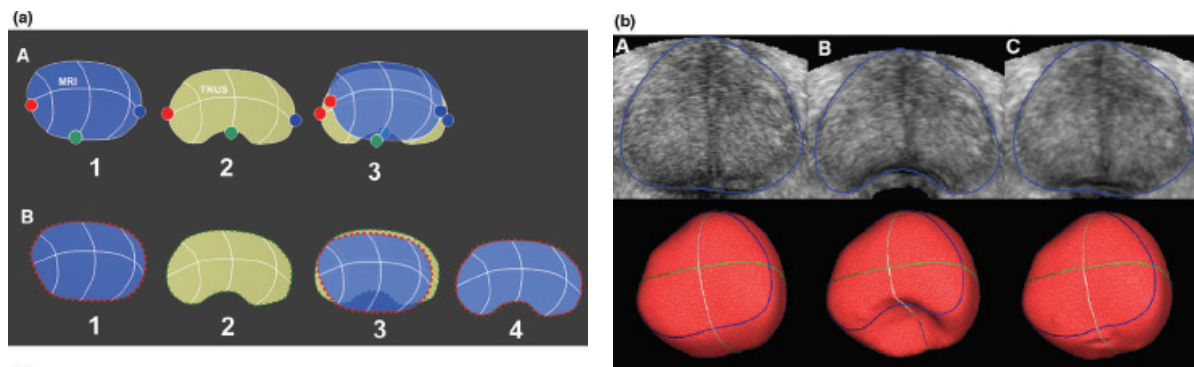
## TRUS-MRI IMAGE REGISTRATION: A PARADIGM SHIFT IN THE DIAGNOSIS OF SIGNIFICANT PROSTATE CANCER

Cornud F<sup>1</sup>, Brolis L, Delongchamps NB, Portalez D, Malavaud B, Renard-Penna R, Mozer P.

<sup>1</sup>Department of Radiology, Hôpital Cochin, Paris, France

Abdom Imaging. Dec 2013

**ABSTRACT:** Accuracy of multiparametric MRI has greatly improved the ability of localizing tumor foci of prostate cancer. This property can be used to perform a TRUS-MR image registration, new technological advance, which allows for an overlay of an MRI onto a TRUS image to target a prostate biopsy toward a suspicious area. Three types of registration have been developed: cognitive-based, sensor-based, and organ-based registration. Cognitive registration consists of aiming a suspicious area during biopsy with the knowledge of the lesion location identified on multiparametric MRI. Sensor-based registration consists of tracking in real time the TRUS probe with a magnetic device, achieving a global positioning system which overlays in real-time prostate image on both modalities. Its main limitation is that it does not take into account prostate and patient motion during biopsy. Two systems (Artemis and Uronav) have been developed to partially circumvent this drawback. Organ-based registration (Koelis) does not aim to track the TRUS probe, but the prostate itself to compute in a 3D acquisition the TRUS prostate shape, allowing for a registration with the corresponding 3D MRI shape. This system is not limited by prostate/patient motion and allows for a deformation of the organ during registration. Pros and cons of each technique and the rationale for a targeted biopsy only policy are discussed.



**Figure 1.** Diagram explaining differences between rigid (non deformable) and elastic (deformable) registration.

(a) Rigid registration. A Three points have been placed on the MRI (1) and on TRUS prostate contour (2). Differences in prostate shape and deformation do not allow for an accurate prostate overlay after rigid registration (3). B Elastic deformation with surface-based registration and organ deformation. Multiple points have been placed on MRI and TRUS prostate contour (1, 2). This first step is a rigid registration which still lacks accuracy owing to the differences in prostate shape (3). An algorithm allows for a deformation of the MRI prostate shape to allow for an accurate registration (4).

(b) Demonstration of the efficiency of elastic deformation. A The original shape of the prostate with its correspondent 3D shape (red image, lower row). B Induction with a mathematical model of a posterior deformation of the prostate (10-mm-diameter sphere to simulate TRUS probe insertion). C After activation of the elastic registration software, the original 3D shape has been rebuilt.



## MULTICENTER TRANSPERINEAL MRI-TRUS FUSION GUIDED OUTPATIENT CLINIC PROSTATE BIOPSIES UNDER LOCAL ANESTHESIA

Jacewicz M<sup>1</sup>, Günzel K, Rud E, Lauritzen P.M, Galtung K.F, Hinz S, Baco E.

<sup>1</sup>Department of Urology, Oslo University Hospital, Oslo, Norway

Urol Oncol. 2020

**INTRODUCTION:** Transperineal Prostate biopsies (TPBx) are usually performed under general anesthesia without image fusion. This study aimed to evaluate prostate cancer (Pca) detection rates (CDR), pain, and adverse events using a novel, free-hand TPBx technique, based on elastic fusion of magnetic resonance imaging (MRI) and transrectal ultrasound (TRUS) under local anesthesia.

**MATERIALS AND METHODS:** This multicenter retrospective study included all consecutive patients scheduled for a TPBx. All had clinical suspicion of Pca, active surveillance scheduled for a re-biopsy, or suspicion of local recurrence after previous treatment. Bi-parametric or multiparametric MRI was performed in all patients and classified as positive in the case of Prostate Imaging-Reporting and Data System (PIRADS) suspicion  $\geq 3$ . At least 1 targeted TPBx was realized from each PIRADS  $\geq 3$  index lesion. Six to 12 systematic random TPBx were done in patients with negative MRI. All biopsies were performed under local anesthesia in an outpatient clinic with MRI-TRUS fusion and the 3D navigation system Trinity Perine (Koelis, France). Any- and clinically significant Pca (csPca) (ISUP gr.  $\geq 2$ ) was recorded. Biopsy-related pain and adverse events were reported according to a visual analogue score of 0–10.

**RESULTS:** In total, 377 patients were included for analyses. The mean age was 67 years (95% Confidence Interval: 66–68) and the median prostate-specific antigen was 7.2 ng/ml (interquartile range [IQR] 4.8–11.0). MRI was negative in 6% and positive in 94%. The median MRI prostate volume was 43 ml (IQR 31–60) and the median MRI index tumor volume was 0.9 ml (IQR 0.5–2.1). The median number of TPBx was 4 (IQR 3–4). The overall detection of any- and csPca was 64% and 52%, respectively. The overall CDR according to PIRADS 3, 4, and 5 was 30%, 70%, and 94%, respectively. In patients with negative MRI, any- and csPca was detected in 23% and 9%, respectively. The median visual analogue score score was 2 (IQR 1–3, range 0–7). Two patients (0.5%) developed postbiopsy infection, of which one developed urosepsis. Treatment requiring haematuria or urinary retention did not occur.

**CONCLUSION:** Free-hand MRI/TRUS fusion-guided and systematic random TPBx in LA is a feasible, safe, and well-tolerated technique for diagnosing Pca.

# CLINICAL PROSTATE CANCER

## MULTICENTER TRANSPERINEAL MRI-TRUS FUSION GUIDED OUTPATIENT CLINIC PROSTATE BIOPSIES UNDER LOCAL ANESTHESIA

JACEWICZ ET AL, UROLOGIC ONCOLOGY, JULY 2020

### PATIENTS

Daily Clinical Practice



**377**

**63**  
years

**7.2**  
ng/mL  
PSA

**43mL**

**0.9mL**



**2**

### METHODS

Transperineal biopsy - KOELIS MRI/US fusion



39% patient received antibacterial prophylaxis



MRI

91% MRI +



**4**

TARGETED BIOPSY COR

6% MRI -

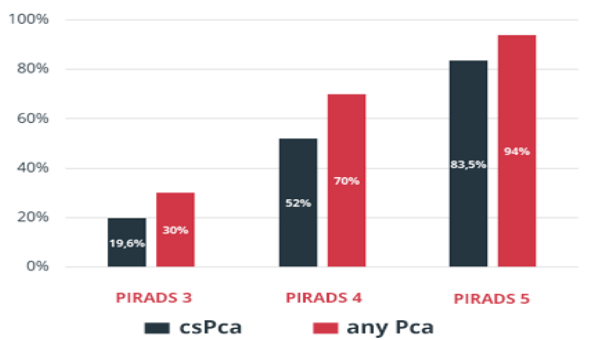


**6-12**

RANDOM BIOPSY

### RESULTS

Detection rate of any cancer and csPca



• 0.5% POSTBIOPSY INFECTION

• MEDIAN VISUAL VAS SCORE (2/10)



### KEY TAKE AWAY

- HIGHER DETECTION RATE
- LOW POSTBIOPSY INFECTION RATE
- WELL-TOLERATED TECHNIQUE

## REFINING THE RISK-STRATIFICATION OF TRANSRECTAL BIOPSY-DETECTED PROSTATE CANCER BY ELASTIC FUSION REGISTRATION TRANSPERINEAL BIOPSIES

Covin B<sup>1</sup>, Roumigué M<sup>1</sup>, Quintyn-Ranty ML, Graff P, Khalifa J, Aziza R, Ploussard G, Portalez D, Malavaud B.

<sup>1</sup>Department of Urology, Institut Universitaire du Cancer, Toulouse, France.

World J Urol 2018

**PURPOSE:** To evaluate image-guided Transperineal Elastic-Registration biopsy (TPER-B) in the risk-stratification of low-intermediate risk prostate cancer detected by Transrectal-ultrasound biopsy (TRUS-B) when estimates of cancer grade and volume discorded with multiparametric Magnetic Resonance Imaging (MRI).

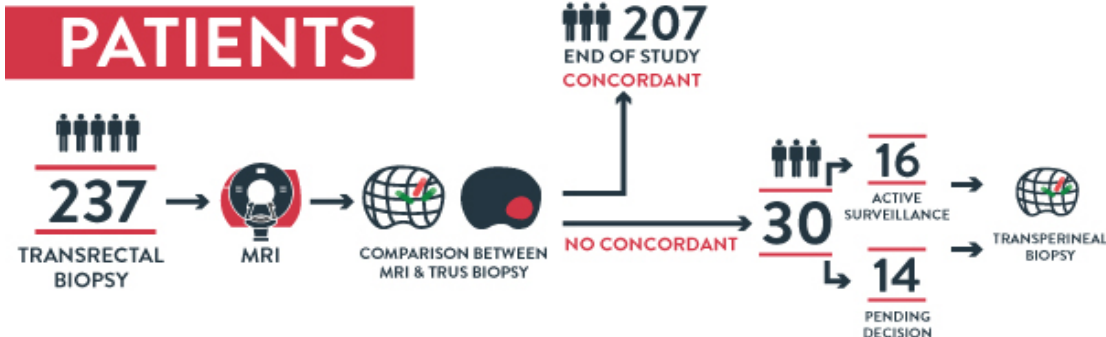
**METHODS:** All patients referred for active surveillance or organ-conservative management were collegially reviewed for consistency between TRUS-B results and MRI. Image-guided TPER-B of the index target (IT) defined as the largest Prostate Imaging-Reporting Data System-v2 $\geq$ 3 abnormality was organized for discordant cases. Pathology reported Gleason grade, maximum cancer core length (MCCL) and total CCL (TCCL).

**RESULTS:** Of 237 prostate cancer patients (1-4/2018), 30 were required TPER-B for risk-stratification. Eight cores were obtained [Median and IQR: 8 (6-9)] including six (IQR: 4-6) in the IT. TPER-B of the IT yielded longer MCCL [Mean and (95%CI): 6.9 (5.0-8.8) vs. 2.6 mm (1.9-3.3),  $p < 0.0001$ ] and TCCL [19.7 (11.6-27.8) vs. 3.6 mm (2.6-4.5),  $p = 0.0002$ ] than TRUS-B of the gland. On TPER-B cores, longer MCCL [Mean and (95%CI): 8.7 mm (6.7-10.7) vs. 4.1 mm (0.6-7.6),  $p = 0.002$ ] were measured in Gleason score-7 cancers. TPER-B cores upgraded 13/30 (43.3%) patients. 14/30 (46.7%) met University College London-definition 1 and 18/30 (60.0%) definition 2, which correlate with clinically significant cancers  $> 0.5$  mL and  $> 0.2$  mL, respectively. 7/16 (43.8%) patients under active surveillance were re-allocated toward prostatectomy ( $n = 5$ ) or radiation therapy ( $n = 2$ ). In 14 patients not yet assigned, TPER-B risk-stratification spurred the selection (13/14, 92.9%) of treatments with curative intent.

**CONCLUSION:** Image-guided TPER-B of the index target provided more cancer material for pathology. Subsequent re-evaluation of cancer volume and grade switched a majority of patients towards higher-risk groups and treatments with curative intent.


REFINING THE RISK STRATIFICATION OF TRANSRECTAL BIOPSY DETECTED PROSTATE CANCER BY ELASTIC FUSION REGISTRATION TRANSPERINEAL BIOPSIES

COVIN ET AL , WORLD J UROL , SEPTEMBER 2018



**METHODS**

TRANSPERINEAL BIOPSY - KOELIS MRI/US FUSION



**RESULTS**

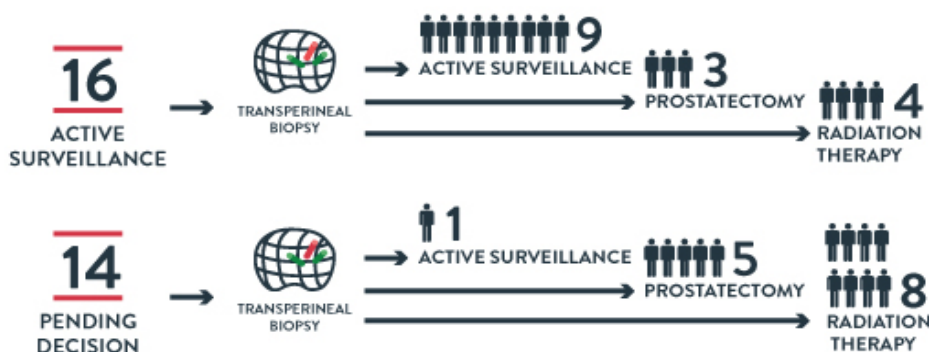
MAXIMUM CANCER CORE LENGTH (MEAN)



TOTAL CANCER CORE LENGTH (MEAN)



RISK STRATIFICATION MODIFICATION



© KOELIS 2018





## INCIDENTALLY DETECTED 18 F-FDG-AVID PROSTATE CANCER DIAGNOSED USING A NOVEL FUSION BIOPSY PLATFORM

Meyer A.R<sup>1</sup>, Leroy A<sup>2</sup>, Allaf M.E, Rowe S.P, Gorin M.A.

<sup>1</sup>The James Buchanan Brady Urological Institute and Department of Urology, Johns Hopkins University School of Medicine, Baltimore, Maryland

<sup>2</sup>KOELIS, Inc., Cambridge, Massachusetts

J Endourol Case Rep. 2019

**BACKGROUND:** Localized prostate cancer rarely undergoes a shift in metabolism towards aerobic glycolysis, a process known as the Warburg Effect. Because of this, positron emission tomography (PET)/CT imaging using 2-deoxy-2-[18F]fluoro-d-glucose (18F-FDG) is uncommonly used to evaluate patients with early-stage prostate cancer. However, men undergoing an 18F-FDG PET/CT for unrelated reasons will on occasion be found to have radiotracer uptake within the prostate gland. The appropriate work-up of these patients is poorly defined

**CASE PRESENTATION:** We present the case of a 61-year-old man with a history of tonsillar squamous cell carcinoma who was incidentally found on 18F-FDG PET/CT to have a hypermetabolic nodule within the prostate. The patient's prostate-specific antigen level was 2.1 ng/cc and digital rectal examination revealed no abnormalities. The patient underwent a targeted prostate biopsy of the lesion using the KOELIS Trinity biopsy platform, which uniquely allows for the real-time overlay of transrectal ultrasonography and PET/CT images. Targeted biopsy revealed Gleason score 4 + 3 = 7 (grade group 3) prostate cancer.

**CONCLUSION:** Although the incidental detection of 18F-FDG uptake within the prostate is uncommon, more than half of all patients will be found to have prostate cancer. Based on this case and our review of the available medical literature, it is our belief that men with incidentally detected uptake of 18F-FDG within the prostate should undergo further evaluation with a prostate biopsy. This recommendation is supported by data suggesting that 18F-FDG-avid prostate cancer represents a more aggressive clinical phenotype.

DIAGNOSTIC ACCURACY : PET/US TARGETED BIOPSY

FUSION TARGETED BIOPSY USING PSMA-PET/CT FOR PROSTATE CANCER DIAGNOSIS IN PATIENTS WITH A PREVIOUS NEGATIVE BIOPSY

Olivares R<sup>1</sup>, Jofre B<sup>2</sup>,González P<sup>2</sup>, Velasco A, Franco C, Román C.

<sup>1</sup>Urology Department of Clínica Santa María, Santiago, Chili  
<sup>2</sup>Imaging Department of Clínica Santa María, Santiago

CAU 2018

**INTRODUCTION:** For patients with a previous negative biopsy but with maintained clinical suspicion for prostate cancer, Multiparametric Magnetic Resonance (MRI)-guided biopsy has demonstrated its usefulness and efficiency, especially, for the diagnosis of a clinically significant disease. Approximately 20% of patients have lesions that are “invisible” to resonance. In these cases, PET-CT could have diagnostic usefulness with the definition of limits and guidance of the sampling during the medical procedure.

**METHODS:**  
 A 57-year-old patient  
 PSA level of 10ng/ml  
 Non suspicious DRE  
 Biopsy: Two previous negative biopsies  
 PET/CT PSMA: Two lesions with increased uptake

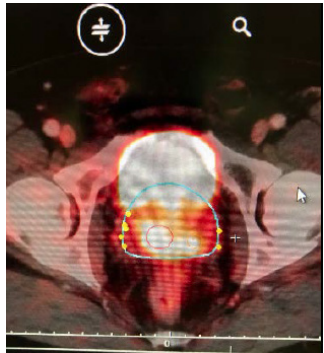


Figure 1: Two radiotracer uptakes on PSMA-PET/CT

**RESULTS:**  
 45-minute procedure  
 US/PET-CT Elastic Fusion using KOELIS Trinity® cartographer  
 5 targeted core samples obtained from the suspect lesions  
 18 additional, random cores using sextant scheme as the reference  
 Anatomical Pathology confirmed a Gleason score of 3+4 in 3/5 of targeted biopsy cores and in 1 among the aleatory sextant biopsy sampling

**CONCLUSIONS:** First report in Latin America about the usefulness of US/PET-CT PSMA Fusion Biopsy for diagnosis of prostate cancer in a patient with previous negative biopsy and no evidence of malignancy in MRI Series involving a higher number of patients will make possible to evaluate the usefulness and the cost-effectiveness in clinical practice.

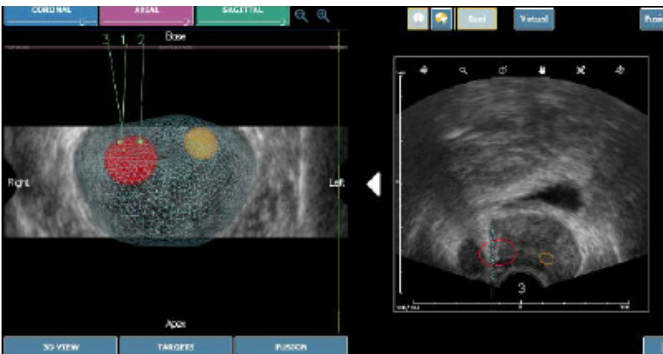


Figure 2: Targets' contour for the targeted biopsy on the US/PET-CT Fusion

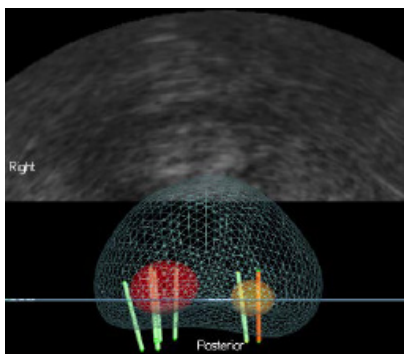


Figure 3: 3D map displaying sample cores

## TRIMODAL (18) F-CHOLINE-PET/MPMRI/TRUS TARGETED PROSTATE BIOPSIES: FIRST CLINICAL EXPERIENCE

J.L. Bonnal<sup>1</sup>, A. Marien, A. Rock, K. El Maadarani, C. Francois, A. Delebarre, D. Berssard, B. Mauroy, P. Gosset, T. Blaire

<sup>1</sup>Hôpital Saint Philibert, Lomme, Groupement des Hôpitaux de l'Institut Catholique de Lille


EAU 2017

**PURPOSE:** In this preliminary study, the feasibility of PET choline compared mpMRI was studied, to define target prostate biopsy. The fusion of these two modalities with 3D echography was to compare the diagnostic performance for primary localization of PCa with mpMRI and the latest generation of PET.

**PATIENTS AND METHODS:** In a prospective single-center study, from December 2014 to October 2016, all patients with PSA above 10ng/ml or patient with medical history of negative prostate biopsy were included. 3D biopsy with KOELIS system, mpMRI and PET scan Choline were done for each patient. The biopsy targets were defined with both modalities and merging was done in real time during prostate biopsy sessions with the 3D echography. A review has been done to exclude patients with missed targets. The results were compared to anatomopathological outcome of the biopsies. Biopsy was done twice for each target at least and randomized biopsy was done outside the target.

**RESULTS:** 31 patients were included, mean PSA was 13.01 (5.32-73). Mean number of biopsy was 16 (13-21) and mean prostate volume was 63.41 cc (25-169). During our learning curve, 4 patients with several negative targets but 1 missed target were excluded for global analysis. However, 3 patients were detected as positive while all targets were not biopsied. Furthermore, the PET fusion analysis failed for one patient. The cancer detection rate was 69%. If the biopsy came back positive for cancer, the PET, the mpMRI or both targets were respectively positive in 72%, 94%, 100%. On average in this population the number of biopsies by target with TEP or mpMRI were respectively 1.77 (1-7), 2.74 (3-11). The TEP and IRM by target were associated with positive biopsies respectively in 43% and 62%. Compared to mpMRI, for one patient only TEP gave a positive target but fail with four other patients. mpMRI was probably best than PET choline for detecting prostate cancer but it could be complementary.

**CONCLUSIONS:** We demonstrate the feasibility of multiple imagery fusion with echography 3D to define localization of prostate cancer. It was very interesting to observe sometimes a great difference in the distribution of PET choline target and mpMRI target in prostate. A new study with the novel ligands targeting prostate specific membrane antigen (PSMA) could improve our clinical results.



*Figure 1: The biopsy procedure was performed after registration of real-time TRUS with mpMRI and choline-PET by the same operator, using 3D TRUS-tracking system. At the time of biopsy, volume data of the mpMRI and PET 18-ch was elastically fused with TRUS. Each target was biopsied twice.*

## REPEAT BIOPSY FOR ACTIVE SURVEILLANCE STRATEGY

## MULTIPARAMETRIC MAGNETIC RESONANCE IMAGING FACILITATES RECLASSIFICATION DURING ACTIVE SURVEILLANCE FOR PROSTATE CANCER

Fujihara A<sup>1</sup>, Iwata T, Shakir A, Tafuri A, Cacciamani G, Gill K, Ashrafi A, Ukimura O, Desai M, Duddalwar V, Stern M, Aron M, Palmer S, Gill I, Abreu A.L.

<sup>1</sup> USC Institute of Urology and Catherine & Joseph Aresty Department of Urology, University of Southern California, Los Angeles, CA, USA

BJUI Inter. 2020

**OBJECTIVE:** To investigate the utility of multiparametric magnetic resonance imaging (mpMRI) in the reassessment and monitoring of patients on active surveillance (AS) for Grade Group (GG) 1 prostate cancer (PCa).

**PATIENTS AND METHODS:** We identified, from our prospectively maintained institutional review board-approved database, 181 consecutive men enrolled on AS for GG 1 PCa who underwent at least one surveillance mpMRI followed by MRI/prostate biopsy (PBx). A subset analysis was performed among 68 patients who underwent serial (at least two) mpMRI/PBx during AS. Pathological progression (PP) was defined as upgrade to GG  $\geq 2$  on follow up biopsy.

**RESULTS:** Baseline MRI was performed in 34 patients (19%). At a median follow-up of 2.2 years for the overall cohort, the PP was 12% (6/49) for Prostate Imaging Reporting and Data System (PI-RADS) 1–2 lesions and 37% (48/129) for the PI-RADS  $\geq 3$  lesions. The 2-year PP-free survival rate was 84%. Surveillance prostate-specific antigen density ( $P < 0.001$ ) and surveillance PI-RADS  $\geq 3$  ( $P = 0.002$ ) were independent predictors of PP on reassessment MRI/PBx. In the serial MRI cohort, the 2-year PP-free survival was 95% for the No-MRI-progression group vs 85% for the MRI-progression group ( $P = 0.02$ ). MRI progression was significantly higher in the PP (62%) than in the No-PP (31%) group ( $P = 0.04$ ). If serial MRI were used for PCa surveillance and biopsy were triggered based only on MRI progression, 63% of PBx might be postponed at the cost of missing 12% of GG  $\geq 2$  PCa in those with stable MRI. Conversely, this strategy would miss 38% of those with upgrading to GG  $\geq 2$  PCa on biopsy. Stable serial mpMRI correlates with no reclassification to GG  $\geq 3$  PCa during AS.

**CONCLUSION:** On surveillance mpMRI, PI-RADS  $\geq 3$  was associated with increased risk of PCa reclassification. Surveillance biopsy based only on MRI progression may avoid a large number of biopsies at the cost of missing many PCa reclassifications.

## REPEAT BIOPSY FOR ACTIVE SURVEILLANCE STRATEGY

## PERFORMANCE OF SYSTEMATIC, MRI-TARGETED BIOPSIES ALONE OR IN COMBINATION FOR THE PREDICTION OF UNFAVOURABLE DISEASE IN MRI-POSITIVE LOW-RISK PROSTATE CANCER PATIENTS ELIGIBLE FOR ACTIVE SURVEILLANCE

Ploussard G<sup>1</sup>, Beauval J-B, Lesourd M, Almeras C, Assoun J, Aziza R, Gautier J-R, Loison G, Portalez D, Salin A, Totton C, Soulié M, Malavaud B, Roumiguié M.

<sup>1</sup>Department of Urology, La Croix du Sud Hospital, IUCT-O, Toulouse, France

World Journ Urol. 2019

**PURPOSE:** To assess the upstaging/upgrading rates of low-risk prostate cancer (PCa) according to the biopsy scheme used (systematic (SB), targeted biopsies (TB), or both) in the setting of positive pre-biopsy MRI.

**PATIENTS AND METHODS:** We included 143 consecutive men fulfilling the Toronto University active surveillance (AS) criteria who underwent a pre-biopsy positive MRI, a combination of SB and software-based fusion TB, and a radical prostatectomy, in two expert centres. The primary endpoints were the pathological upgrading and upstaging rates. Overall unfavourable disease (OUD) was defined by any pT3-4 and/or pN1 and/or  $\geq$ GG 3.

**RESULTS:** Using TB alone would have missed 21.7% of cancers including 16.7% of  $\geq$ GG 3. The use of TB was significantly associated with a lower risk of  $\geq$ Grade Group (GG) 3 disease ( $p < 0.006$ ) in RP specimens. Combination of SB and TB lowered this risk by 39%, compared with TB alone. The biopsy scheme did not affect the upstaging rates which were substantial even in case of combination scheme (from 37 to 46%). OUD was detected in approximately 50% of cases. The presence of high grade on TB was the only independent predictive factor for both  $\geq$ GG 2 ( $p = 0.015$ ) and  $\geq$ GG 3 ( $p = 0.023$ ) in RP specimens.

**CONCLUSION:** High grade on TB biopsies represented the major predictor of upgrading. Combination of SB and TB better defined the sub-group of patients having the lowest risk of reclassification, compared with TB or SB alone. The risk of non-organ-confined disease remained high, and could not be accurately predicted by MRI or systematic/targeted biopsy features.

## REPEAT BIOPSY FOR ACTIVE SURVEILLANCE STRATEGY

## A NOVEL TECHNIQUE USING THREE-Dimensionally DOCUMENTED BIOPSY MAPPING ALLOWS PRECISE RE-VISITING OF PROSTATE CANCER FOCI WITH SERIAL SURVEILLANCE OF CELL CYCLE PROGRESSION GENE PANEL

Ukimura O<sup>1</sup>, Gross ME, de Castro Abreu AL, Azhar RA, Matsugasumi T, Ushijima S, Kanazawa M, Aron M, Gill IS.

<sup>1</sup>USC Institute of Urology, Keck School of Medicine, University of Southern California, Los Angeles, California.

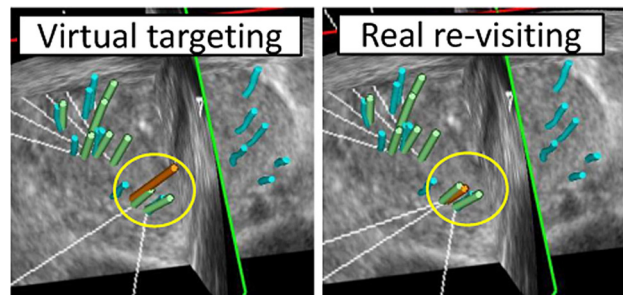
The Prostate. 2015

**BACKGROUND:** Conventional systematic biopsy has the shortcoming of sampling error and reveals «no evidence of cancer» with a rate of >50% on active surveillance (AS). The objective of this study is to report our initial experience of applying a 3D-documented biopsy-mapping technology to precisely re-visit geographically documented low-risk prostate cancer and to perform serial analysis of cell-cycle-progression (CCP) gene-panel.

**METHODS:** Over a period of 40 months (1/2010-4/2013), the 3D-biopsy-mapping technique, in which the spatial location of biopsy-trajectory was digitally recorded (Koelis), was carried out. A pair of diagnostic (1st-look) and surveillance (2nd-look) biopsy were performed per subject (n=25), with median interval of 12 months. The documented biopsy-trajectory was used as a target to guide the re-visiting biopsy from the documented cancer focus, as well as the targeted field-biopsy from the un-sampled prostatic field adjacent to negative diagnostic biopsies. The accuracy of re-visiting biopsy and biopsy-derived CCP signatures were evaluated in the pair of the serial biopsy-cores.

**RESULTS:** The 1st-look-biopsy revealed a total of 43 cancer lesions (1.7 per patient). The accuracy of re-visiting cancer was 86% (37/43) per lesion, 76% (65/86) per core, and 80% (20/25) per patient. This technology also provided an opportunity for 3D-targeted field-biopsy in order to potentially minimize sampling errors. The CCP gene-panel of the 1st-look (-0.59) versus 2nd-look (-0.37) samples had no significant difference (P=0.4); which suggested consistency in the molecular signature of the known cancer foci during the short-time interval of median 12 months. Any change in CCP of the same cancer foci would be likely due to change in sampling location from the less to more significant portion in the cancer foci rather than true molecular progression. The study limitations include a small number of the patients.

**CONCLUSION:** The 3D-documented biopsy-mapping technology achieved an encouraging re-sampling accuracy of 86% from the known prostate cancer foci, allowing the serial analysis of biopsy-derived CCP signatures.



**Figure 1.** The re-visiting biopsy technique using the pair of “virtual” and “real” targeting. The re-visiting biopsy technique is demonstrated in Figure 2 by the pair of “virtual” (long orange trajectory, circled in yellow in the left of Fig. 3) and “real” biopsies (short orange trajectory, circled in yellow in the right of Fig. 2), intentionally sampling from the previously positive targets in the location of the right-apex-medial. Because the virtual targeting seemed 3–4 mm too lateral to reach the target, the direction of the real biopsy was further corrected to bring it closer to the target. Note that one core (green trajectory) had already been sampled during the current 2nd-look biopsy from the same positive target with the same re-visiting technique. These two re-visiting cores in the 2nd look biopsy were positive for cancer. The overlaid image demonstrates that the pair of green and orange trajectories of the re-visiting technique almost corresponded (or were located within 1–2 mm) with the blue trajectory of the positive core at the right-apex-medial on the 1st-look biopsy.

## VALIDATION OF THE EUROPEAN SOCIETY OF UROGENITAL RADIOLOGY SCORING SYSTEM FOR PROSTATE CANCER DIAGNOSIS ON MULTIPARAMETRIC MAGNETIC RESONANCE IMAGING IN A COHORT OF REPEAT BIOPSY PATIENTS

Portalez D<sup>1</sup>, Mozer P, Cornud F, Renard-Penna R, Misrai V, Thoulouzan M, Malavaud B.

<sup>1</sup>Department of Radiology, Clinique Pasteur, Toulouse, France

World Journ Urol. 2019

**BACKGROUND:** Wide variations in acquisition protocols and the lack of robust diagnostic criteria make magnetic resonance imaging (MRI) detection of prostate cancer (PCa) one of the most challenging fields in radiology and urology.

**DESIGN, SETTING, AND PARTICIPANTS:** An institutional review board-approved multicentric prospective study; 129 consecutive patients (1514 cores) referred for mpMRI after at least one set of negative biopsies.

**INTERVENTION:** Transfer of mpMRI-suspicious areas on three-dimensional (3D) transrectal ultrasound images by 3D elastic surface registration; random systematic and targeted cores followed by core-by-core analysis of pathology and mpMRI characteristics of the core locations. The ESUR scores were assigned after the procedure on annotated Digital Imaging and Communications in Medicine archives.

**OUTCOME MEASUREMENTS AND STATISTICAL ANALYSIS:** Relationships between ESUR scores and biopsy results were assessed by the Mann-Whitney U test. The Yates correction and Pearson  $\chi^2$  tests evaluated the association between categorical variables. A teaching set was randomly drawn to construct the receiver operating characteristic curve of the ESUR score sum (ESUR-S). The threshold to recommend biopsy was obtained from the Youden J statistics and tested in the remaining validation set in terms of sensitivity, specificity, positive predictive value, negative predictive value, and accuracy.

**RESULTS AND LIMITATIONS:** Higher T2-weighted, dynamic weighted imaging and dynamic contrast-enhanced ESUR scores were observed in areas yielding cancer-positive cores. The proportion of positive cores increased with the ESUR-S aggregated in five increments (ESUR-S 3-5: 2.9%; ESUR-S 6-8: 11.1%; ESUR-S 9-10: 38.2%; ESUR-S 11-12: 63.4%; and ESUR-S 13-15: 83.3%;  $p < 0.0001$ ). A threshold of ESUR-S  $\geq 9$  exhibited the following characteristics: sensitivity: 73.5%; specificity: 81.5%; positive predictive value: 38.2%; negative predictive value: 95.2%; and accuracy: 80.4%. Although the study was not designed to compare repeat biopsy strategies, more targeted cores than random systematic cores were found to be positive for cancer (36.3% compared with 4.9%,  $p < 0.00001$ ).

**CONCLUSION:** In the challenging situation of repeat biopsies, the ESUR scoring system was shown to provide clinically relevant stratification of the risk of showing PCa in a given location.

## FOCAL TREATMENT

## A NOVEL FOCAL THERAPY – MICROWAVE ABLATION UNDER ORGAN-BASED TRACKING (OBT) FUSION IN PATIENTS WITH LOCALIZED PROSTATE CANCER: PRELIMINARY RESULTS OF FOSTINE 01B PILOT STUDY

Peltier A<sup>1</sup>, Assenmacher G, Aoun F, Hawaux E, Limani K, Sirtaine N, Ben Aziz M, Lefebvre Y, Lemort M, Van Velthoven R.

<sup>1</sup> Institut Jules Bordet, Departement of Urology, Brussels, Belgium

Eur Urol Open Sci. 2020

**INTRODUCTION ET OBJECTIVES:** Through an ablate-and-resect study, we evaluated the feasibility, safety and histological effects of very low loss (VLL) microwave ablation, performed transrectally under real-time MRI/TRUS image registration and 3D mapping, in patients with localized prostate cancer (PCa).

**MATERIALS AND METHODS:** Patients with a detectable index lesion on mpMRI, PSA level <20 ng/mL and wishing to undergo a prostatectomy in case of significant PCa on biopsy were eligible for this study approved by Ethics Committee. Targeted biopsies of the index lesion were performed by using an ultrasound-MRI image fusion system with OBT-registration (Trinity®, KOELIS, France) to provide quality control. Targeted cores were analyzed intraoperatively with an extemporaneous analysis. If positive, the patients were treated during the same session by a targeted focal microwave ablation using a single 18G needle inserted transrectally under sedation. Predictive ablation charts obtained with the microwave generator (TATO, Biomedical Srl, Italy) through in vitro experiments were used to choose the duration and power of the treatment. Treated patients were followed-up for 4 to 6 weeks and the planned radical prostatectomy was performed. All patients underwent uroflowmetry test and filled the self-administered questionnaires (IPSS, IPSS-QOL, IIEF-5, and MSHQ-EjD-SF) before the intervention, at 7 days and 1 month after the procedure. A mpMRI of the treated prostate was performed at 7 days. After radical prostatectomy, whole-mount histology served to define the ablation boundaries and dimensions in the prostate. A total of 10 patients will be operated.

**RESULTS:** From January to June 2019, 5 patients participated in this ablate-and-resect study without therapeutic intent. Microwave ablation was performed on 4 patients. One patient did not receive the treatment due to negative targeted biopsies and was exited from the study. Another one withdrew his consent after microwave ablation and thus did not undergo radical prostatectomy. He is now under active surveillance. All procedures were performed under sedation in an outpatient setting, with a median intervention time of 81.5 min [63.75-96.5]. After 4 interventions, no patient reported any pain and no serious adverse event was observed. The early postoperative mpMRI showed consistent devascularization on the T1 DCE MRI at the treatment site. A sharp necrosis was also observed on the whole-mount sections. Further interventions will allow to compare clinical observations with the predictive charts.

**CONCLUSION:** Our pilot study demonstrated that microwave ablation guided by OBT-fusion in patients with localized PCa is safe, feasible and easily deliverable in an outpatient setting. Histopathological analyses confirm a well-delimited ablation shape.



## TRAITEMENT FOCAL TRANSRECTAL PAR MICRO-ONDE DU CANCER DE LA PROSTATE LOCALISÉ DE RISQUE FAIBLE ET INTERMÉDIAIRE : RÉSULTATS PRÉLIMINAIRES

Barry Delongchamps N<sup>1</sup>, Schull A, Saighi D, Zerbib M, Peyromaure M.

<sup>1</sup>Hôpital Cochin, Paris, France

Progrès en Urol. 2019

**OBJECTIFS:** L'objectif de cette étude était de tester la faisabilité, la précision et la sécurité d'un traitement transrectal de la tumeur index par micro-onde, guidée par fusion d'image élastique IRM-échographie, chez 10 patients ayant un cancer de la prostate de risque faible ou intermédiaire.

**MÉTHODES:** Les patients éligibles devaient avoir un PSA < 15 ng/mL, une tumeur index à plus de 5 mm du rectum, et ayant un score de Gleason ≤ 3 + 4. Le système de guidage par cartographie 3D Trinity (KOELIS) était utilisé pour le diagnostic, le traitement et le suivi. Un applicateur de 18G délivrait les micro-ondes par voie transrectale sous anesthésie générale. Le critère d'évaluation principal était la nécrose complète du volume cible sur l'IRM à j7. Les critères d'évaluation secondaire étaient la tolérance urinaire et sexuelle. Des biopsies ciblées étaient réalisées dans la zone traitée à 6 mois.

**RÉSULTATS:** Les caractéristiques cliniques et carcinologiques sont résumées dans les Tableau 1, Tableau 2. La totalité des patients ont pu être traités selon le protocole. La durée moyenne de l'anesthésie générale était de 82 (44–170) minutes. Aucune douleur ni aucun autre effet indésirable n'a été observé en postopératoire immédiat et pendant la durée de l'étude. Les mictions ont repris de manière spontanée dans les deux heures suivant l'intervention. À j7, le volume de nécrose recouvrait totalement le volume cible chez 8 (80 %) patients. Après un suivi de 6 mois, aucune modification des scores IPSS et IIEF5 n'a été observée (Tableau 3). Les biopsies réalisées dans la zone présumée traitée montraient la persistance de cancer de Gleason 3 + 3 et 3 + 4 chez 3 (30 %) et 2 (20 %) patients, respectivement.

**CONCLUSION:** Ces résultats suggèrent que le traitement transrectal par micro-onde guidé par fusion d'image IRM-échographie est faisable, précis et bien toléré. Plus de patients sont nécessaires pour mieux évaluer le résultat carcinologique à long terme.

## FOCAL TREATMENT

### 3D TARGETED FOCAL CRYOTHERAPY TREATMENT: CASE REPORT OF THE FIRST PROCEDURE AT OUR INSTITUTION

S. Crouzet<sup>1</sup>, P. Moldovan<sup>2</sup>

<sup>1</sup> Department of Urology, Radiology

<sup>2</sup>Hôpital Edouard Herriot, Lyon, France

Poster FTI 2019

**INTRODUCTION:** Focal treatment is an emerging solution, which yields high interest as an optimal compromise between radical treatment and active surveillance. Nevertheless, this approach requires, in addition to a focally applied energy, an adequate targeting to properly place the energy. The feasibility of focal targeted cryotherapy using a fusion and mapping platform is here investigated on a patient.

**METHODS AND MATERIALS:** A 71-years-old patient with a chemical recurrence following external beam radiotherapy for prostate cancer, with suspicious foci identified on Choline-PET scan and confirmed by transrectal-targeted biopsy gave consent to receive a targeted and focal cryotherapy treatment. No other tumor site demonstrated on complete workup. The patient was contraindicated for HiFu treatment (rectal stenosis following the initial treatment). A 3D multimodal cartographer (TRINITY®, KOELIS, Meylan, France) and associated accessories (Perine 3D motorized ultrasound probe, SteadyPro mechanical probe holder and needle guides) were used to delineate the region to be treated (MRI/PET-CT/transrectal ultrasound fusion), to guide the cryoprobes implantation and to monitor the focal treatment performed under transperineal access. The cryotherapy system (Visuallce system and IceSphere cryoprobes, GALIL, Arden Hills, USA) delivered the cryotherapy treatment. Two cryoprobes were placed in the region of interest to be treated under 3D guidance, as well as one thermosensor in the recto-prostatic fascia.

**RESULTS:** Planning, targeting, and monitoring have been done successfully. The targeting procedure, from the beginning of the fusion to the end of the implantation, lasted 27 minutes and the treatment 33 minutes. 3D ultrasound imaging was used during the procedure to confirm treatment delivery in the targeted area. No pain or adverse effects have been reported. The real-time mapping capacities of the cartography system allowed to guide the cryoprobes in the anatomical volume, improving accuracy and speeding up the procedure. All the treatment information has been gathered in a 3D prostate map which will allow an effective follow-up of the patient.

**CONCLUSION:** Targeted focal cryotherapy using 3D cartography is feasible and allows to plan, guide, monitor and record such a treatment with precision and safety. This tool will be used in clinical routine at our institution.

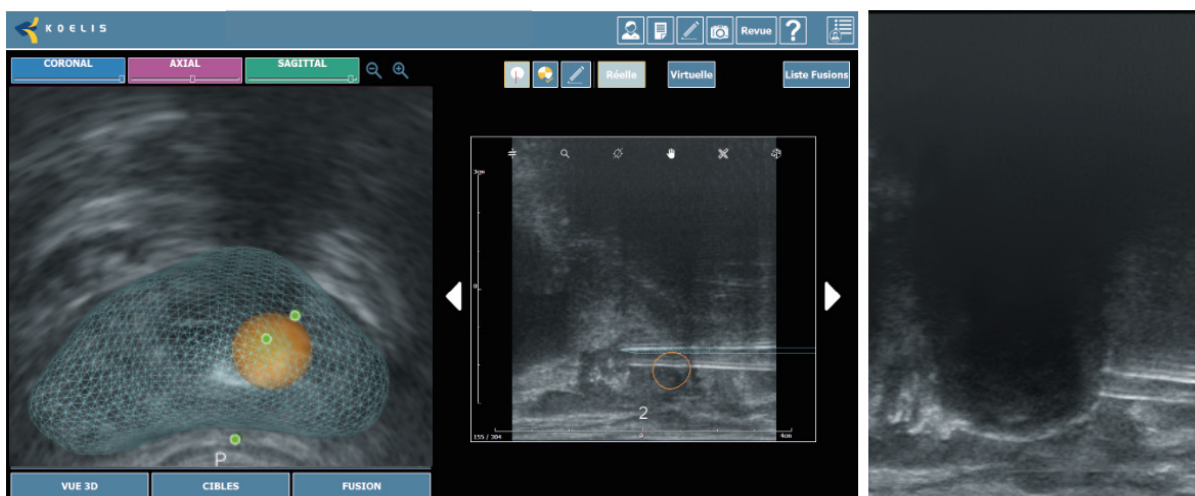


Figure 1: The real-time mapping capacities of the cartography system allowed to guide the cryoprobes in the anatomical volume.



# BIBLIOGRAPHY

|   |    |
|---|----|
| 2019 – Roumiguie M et al. – Improvement of the intermediate risk prostate cancer sub-classification by integrating MRI and fusion biopsy features .....   | 4  |
| 2018 – Oderda M et al. – Int J Urol – Accuracy of elastic fusion biopsy in daily practice: Results of a multicenter study of 2115 patients.....   | 5  |
| 2018 – Rouvière O et al. – Lancet Oncol – use of prostate systematic and targeted biopsy on the basis of multiparametric MRI in biopsy-naïve patients (MRI-FIRST): a prospective, multicenter, paired diagnostic study .....                        | 7  |
| 2018 – Kasivisvanathan V et al. – NEJM – MRI-targeted or standard biopsy for prostate-cancer diagnosis .....  | 8  |
| 2017 – Shin T et al. – BJU Int – detection of prostate cancer using magnetic resonance imaging/ultrasonography fusion targeted biopsy in African American men .....   | 9  |
| 2016 – Baco E et al. – Eur Urol – a randomized controlled trial to assess and compare the outcomes of two-core prostate biopsy guided by fused magnetic resonance and transrectal ultrasound images and traditional 12-core systematic biopsy ..... | 10 |
| 2016 – Klein J et al. – Urol Int – Transrectal ultrasound-guided prostate biopsy for cancer detection: performance of 2D, 3D and 3D-MRI fusion targeted techniques.....   | 11 |
| 2015 – Renard Penna R et al. – Radiology – Prostate imaging reporting and data system and LIKERT scoring system: multiparametric MR imaging validation study to screen patients for initial biopsy  | 12 |
| 2014 – Mozer P et al. – BJUI – first round of targeted biopsies using magnetic resonance imaging/ultrasonography fusion compared with conventional transrectal ultrasonography-guided biopsies for the diagnosis of localised prostate cancer ..... | 13 |
| 2013 – Peltier A et al. – Hindawi – 3D versus 2D systematic transrectal ultrasound-guided prostate biopsy: higher cancer detection rate in clinical practice .....  | 14 |
| 2009 – Mozer P et al. – J US Med –mapping of transrectal ultrasonographic prostate biopsies: quality control and learning curve assessment by image processing .....  | 15 |
| 2018 – Cornud F et al. – Radiology – Precision matters in MR imaging-targeted prostate biopsies: evidence from a prospective study of cognitive and elastic fusion registration transrectal biopsies  | 16 |
| 2013 – Cornud F et al. – Abdom Imaging – TRUS-MRI image registration: a paradigm shift in the diagnosis of significant prostate cancer .....  | 18 |
| 2020 – Jacewich M et al. – Multicenter transperineal MRI-TRUS fusion guided outpatient clinic prostate biopsies under local anesthesia .....  | 20 |
| 2018 – Covin B et al. – world J urol – Refining the risk-stratification of transrectal biopsy-detected prostate cancer by elastic fusion registration transperineal biopsies .....  | 21 |
| 2019 – Meyer R et al. – Incidentally Detected 18 F-FDG-Avid Prostate Cancer Diagnosed Using a Novel Fusion Biopsy Platform.....   | 24 |

|  |    |
|--|----|
| 2018 – Olivares R et al. – EAU: fusion targeted biopsy using PSMA-PET/CT for prostate cancer diagnosis in patients with a previous negative biopsy.....  | 25 |
| 2017 – Bonnal J L et al. – EAU – Trimodal (18) f-choline-PET/mp-MRI/trus targeted prostate biopsies: first clinical experience .....   | 26 |
| 2020 – Fujihara A et al. – Multiparametric magnetic resonance imaging facilitates reclassification during active surveillance for prostate cancer .....  | 27 |
| 2019 – Ploussard G et al. – Performance of systematic, MRI-targeted biopsies alone or in combination for the prediction of unfavorable disease in MRI- positive low-risk prostate cancer patients eligible for active surveillance ..... | 28 |
| 2015 – Ukimura O et al. – The Prostate - A novel technique using three-dimensionally documented biopsy mapping allows precise re-visiting of prostate cancer foci with serial surveillance of cell cycle progression gene panel .....    | 29 |
| 2012 – Portalez D et al. – Validation of the European Society of Urogenital Radiology scoring system for prostate cancer diagnosis on multiparametric magnetic resonance imaging in a cohort of repeat biopsy patients .....             | 30 |
| 2020 – Peltier A et al. - EAU - A novel focal therapy – microwave ablation under Organ-Based Tracking (OBT) in patients with localized prostate cancer: Preliminary results of Fostine 01b pilot study .....                             | 31 |
| 2019 - Barry Delongchamps N et al. - AFU - Traitement focal transrectal par micro-onde du cancer de la prostate localisé de faible risque et intermédiaire : résultats préliminaires.....  | 32 |
| 2019 – Crouzet S et al. - FTI - 3D Targeted focal cryotherapy treatment: case report of the first procedure at our institution.....  | 33 |



## "Health innovation as a passion"

KOELIS, The Prostate Care Company, has assisted urologists and radiologists from around the world in their routine clinical practice since 2006, providing the latest technology for personalized prostate cancer planning and management, from biopsy and treatment to active surveillance.

Focused on developing advanced, targeted and less invasive solutions, KOELIS is committed to creating and bringing to the market a new paradigm in prostate cancer care, where physicians can offer the most personalized answers to their patients, avoiding any under or overtreatment and preserving quality of life. Thanks to cutting-edge imaging tools like Trinity® cartographer, which combines multiple imaging modalities with full 3D ultrasound, any suspicious lesion is characterized in a detailed 3D prostate map, offering a comprehensive and multiparametric approach and enhancing diagnostic confidence.

The team at KOELIS innovates every day in collaboration with world-renowned universities and hospitals to offer physicians new advancements in imaging and a greater field of view, a must-have in active surveillance and targeted treatment. Based in Grenoble and Boston, KOELIS technology has been featured in more than 60 clinical publications and treats more than 250,000 patients worldwide, including patients in Europe, United States, Canada, Japan, Australia, South America and the Middle East.

### **KOELIS SAS**

16 chemin du Vieux Chêne  
38240 Meylan (Grenoble) - France

### **KOELIS Inc. USA**

185 Alewife Brook Parkway Suite 410  
Cambridge MA 02138 - USA

### **KOELIS Hong Kong**

21/F, On Hing Building  
1 On Hing Terrace, Central - Hong Kong

 [www.koelis.com](http://www.koelis.com)

 KoelisBx

 KOELISSAS

 KOELIS

 Koelis

 [info@koelis.com](mailto:info@koelis.com)